

IX. *On the Structure and Development of the Liver.* By C. H. JONES, M.D.
 Communicated by Sir BENJAMIN COLLINS BRODIE, Bart., F.R.S.

Received June 16,—Read June 17, 1847.

IN venturing to offer a second communication to the Royal Society respecting the structure of the liver, I feel the rather anxious to do so, that I may have an opportunity of correcting an error and supplying a deficiency which existed in my previous paper. In the following observations I purpose to present some account of the structure of the liver examined in the ascending series of animals, and also to describe the several stages of its evolution in the embryo; in this way I trust I may be able to exhibit the characteristic structural features of the organ as it exists in Man and the higher animals, and also to determine the true place which ought to be assigned to it in a classification of the various glandular organs occurring in the same.

I am not aware that any detailed account of the structure of the liver has been recently published, except that by M. NATALIS GUILLOT, which however, so far as I comprehend it, does not seem to be one that can be readily accepted; the idea that the minute biliary ducts and lymphatics originate together in a common network, is *à priori* improbable, and entirely opposed to conclusive evidence (as I think), which will be subsequently adduced. A very interesting paper on the structure and function of the liver has also appeared in the 4th volume of the Guy's Hospital Reports, from the pen of Dr. WILLIAMS; to his labours I shall several times have occasion to refer, but it will be seen that I differ from him in several particulars, especially respecting the importance of the basement or limitary membrane.

Commencing with the Bryozoon polype as the lowest individual in the animal series in which distinct traces of a liver have been discovered, we find that (according to Dr. FARRE and Professor OWEN) there are a number of follicles filled with a rich brown secretion, which open into a distinct compartment of the stomach; these doubtless constitute an hepatic organ.

In the Asterias, where though the several systems of organs are sketched out, they yet remain without any appearance of concentration and high individual development, there exists considerable doubt as to the part of the digestive system to which the function of a liver is to be attributed; the most usual opinion seems to regard the ramified appendage found at the dorsal aspect of the stomach as having this character. Dr. WILLIAMS, however, considers it more probable that the layer of cells, lining the dilated cæca of the prolongations of the digestive sac into the rays, discharges

the office of an hepatic apparatus, grounding his opinion on a comparison of the secreting elements in the two organs. My own examination of the dorsal appendage of the stomach does not lead me to agree with Dr. WILLIAMS, in excluding it from participating in the function of a liver; I find it to consist of cæcal follicles which present occasional bulgings; the diameter of these is about $\frac{1}{200}$ th of an inch; they lie packed together in groups which are easily visible to the naked eye: in structure they consist of an homogeneous membrane, which encloses a mass of nuclear granules varying in size from $\frac{1}{9-4000}$ th of an inch; also granular globules, oval or circular transparent vesicles, yellow amorphous matter and oil-drops; between these and the contents of the gastric cæca I did not observe any remarkable difference; nevertheless, I do not mean to imply that the dorsal appendage serves, like the gastric cæca, for the reception of the chyle; but only that, admitting the secretory apparatus of the latter may possibly perform the office of producing bile, there seems no sufficient ground, from difference of structure, for supposing the former to be destined to a different purpose. I ought, however, to mention that in one or two specimens I examined, the structure of the appendage in question corresponded more nearly to the account given of it by Dr. WILLIAMS, but this appeared to me to be a deviation from the natural condition; nor indeed have I ever observed anything which could lead me to assent to the opinion that it represents a pancreas, an organ which first manifests itself unequivocally in the class of Fishes, and exhibits in the different genera so many beautiful stages of progressive complication.

In the Echinidæ, another kindred family, we find the alimentary canal, apparently of great simplicity, passing from the wonderful dental apparatus on one side, to the opposite pole of its elaborately constructed shell, performing only a few gyrations in its course; a few salivary cæca are described as entering the canal just before the œsophagus commences, but no mention is made of any structure serving the purpose of a liver; I have, however, found in the delicate walls of the intestine a layer of elongated follicles, much resembling the gastric tubuli of higher animals; these occupy the whole thickness of the intestinal wall, and are closely in apposition with each other; their colour is a deep yellow; they consist of nuclear granules and amorphous matter, with probably a yellow fluid; these materials seem to cohere simply together, and not to be contained in tubes of homogeneous membrane; the diameter of the follicle-shaped masses measures about $\frac{1}{143}$ rd of an inch. If I be correct in supposing these follicles to secrete a fluid analogous to bile, it would give additional probability to the opinion of Dr. WILLIAMS respecting the function of the gastric cæca of the Asterias.

In the class of Annelides we may expect to find the hepatic apparatus in a very simple and primitive form, corresponding to the general configuration, which exhibits in so marked a manner the law of irrelative repetition. I shall describe the minute structure of the hepatic gland in three different instances, where its existence and position are satisfactorily ascertained, viz. in the Earthworm (*Lumbricus terrestris*), the

Leech (*Hirudo medicinalis*), and the Sandworm (*Arenicola Piscatorum*): among these we shall find some instructive and remarkable differences, the existence of which seems to indicate clearly that we must not rely too much on finding exact analogy of structure in any organ, even in the individuals of the same class. In the Earthworm, a thin yellow stratum is found applied over a great part of the outer surface of the intestine; it adheres intimately to it, and seems to be moulded on the convexities of the sacculi, not dipping deeply into the furrows by which they are separated. I have already described this yellow layer as consisting of dark-yellow masses, the majority of which cannot be seen to have an enveloping cell-membrane, while in others it is clearly perceptible though of extreme tenuity; the masses, with or without this envelope, are often seen elongated into a conical form, the apex directed towards the intestine, to which it often adheres pretty firmly; from this circumstance I formerly conceived that the biliary secretion was discharged by the bursting of the cells into the cavity of the intestine, each cell representing for a short space an attached follicle, and it is not impossible that this may be the case to some extent. But there is another mode in which the bile may come to exert its action on the chyle (if such indeed be necessary), viz. by the latter percolating the coats of the intestine, and consequently the layer of hepatic substance, before it is absorbed by the ramifications of the deep abdomino-dorsal vessel. This latter opinion seems to be strongly supported by the unquestionable condition of another part of the intestinal apparatus, known by the name of Typhlosole: this blind tube, which is beautifully plicated on its surface, extends along the dorsal aspect of the intestine from the gizzard nearly as far as the vent. In structure it consists of a strong homogeneous membrane, covered by a layer of ciliary epithelium, continuous with that which may be often seen on the rest of the intestinal surface, while internally it is lined by a thick stratum of biliary cells, almost precisely similar to those on the exterior of the intestine, and forming with them one continuous system. Now the typhlosole thus seems to be an inflection of the intestinal wall for the purpose of straining off the chyle from the coarse mass of the ingesta; and as it is certain that the biliary matter is not discharged from the cells which line it into the cavity of the intestine, it seems also probable, that at other parts of the intestinal surface the process is the same, the chyle transuding through them as it does through the membrane of the typhlosole.

In the Leech, as Prof. OWEN has described it, the hepatic apparatus appears as a brown tissue, extending along the alimentary canal between the nervous cords and the mucous glands, and also upon the dorsal aspect of the anterior part of the cavity. It is composed, he states, of a congeries of elongated, convoluted and irregularly constricted follicles, which are united in groups by the confluence of their ducts into a single slender excretory tube: that this tissue, so well described, is truly the hepatic organ, cannot for a moment be doubted by any who have examined it with the microscope, the follicles being filled with minute spherules of a deep yellow colour, resembling precisely those which crowd the biliary cells in the Earthworm. Regarding it then

as the homologue of the hepatic apparatus we have just examined, I will enter on a rather more particular account of it, which will disclose I think some characters illustrative of hepatic structure in general. It may be described as consisting of two portions, one in which the constituent cells are free, entirely separate from each other, or only fused together in very small groups, and another in which the cells are completely fused together so as to represent either simple undilated tubes, or tubes irregularly constricted and bulged at intervals; the former is evidently that part of the organ where the production of fresh cells takes place; these are seen at first as granular cells with envelopes more or less distinct, but having only imperfect traces of nuclei; subsequently the characteristic biliary spherules appear in them, and at last fill them completely. Now the cells becoming developed in this manner (and they proceed exactly in a similar manner in the Earthworm) may either become fused together to constitute the tubes above described, or they may lose all trace of an enveloping membrane; their component spherules separating from each other, and the cell at last undergoing complete disintegration on the spot where it had been originally formed, while its elaborated contents are probably absorbed into the circulating stream, from whence as plasma they had proceeded. The contents of the tubes are doubtless poured into the intestine, while the débris of the free parenchymal cells are scattered throughout the surrounding tissue, and thus in this low Annelide we seem to recognise a division of the hepatic apparatus into two portions, similar to those which we shall shortly distinguish in the higher animals; these have probably separate functions, the tubular influencing by its secretion the intestine and its contents, while the parenchymal seems adapted to supply material directly for the use of the respiratory process.

In the Arenicola, the biliary cells are of a lighter colour than in the Leech or Earthworm; they are at first of a pale granular aspect and often exhibit nuclei; subsequently they acquire dark oily-looking contents, and often change their form, becoming remarkably elongated; their diameter varies from $\frac{1}{1000}$ to $\frac{1}{800}$ th of an inch. If the outer surface of the intestine be examined with a low power, it is found to present the convexities of numerous short sacculi with intervening furrows, and to be perfectly even and defined, while the inner surface, on the contrary, has a flocculent, almost ragged appearance. This effect is due to the disposition of the cells, which form a moderately thick stratum, resting on an homogeneous membrane, the sole constituent of the intestinal wall; the cells are therefore actually in the cavity of the intestine, and in immediate contact with its contents; they contrast herein remarkably with those of the Earthworm, which we have seen to lie on the outside, for the cells of the Sandworm may be completely removed by washing the inner surface of the intestine, while those of the Earthworm can be thus detached only from the exterior.

These three instances from among the Annelides seem to exhibit the extreme varieties of condition which the hepatic apparatus is capable of assuming. In the Earthworm

it is wholly parenchymal, in the Sandworm wholly included by the intestinal membrane, while in the Leech it is of a mixed kind, consisting partly of tubes continuous with the intestine and partly of free parenchymal cells.

In the class of Insects, however widely the external form and the organs of the animal functions may vary, the hepatic apparatus preserves a remarkable uniformity, consisting of long slender cylindrical tubes varying in number from 4 to 200. Besides these tubes however, of whose truly hepatic character but little if any doubt can I think exist, there is another structure whose function is more doubtful; this is the so-called adipose tissue, which Mr. NEWPORT believes to serve as a reservoir of nutriment, and also to fulfill in some way the office of lymphatic vessels, while BURMEISTER, OKEN and TREVIRANUS agree in regarding it as a portion of the hepatic apparatus. The opinion of these latter authorities is that to which I incline, for reasons which I will state, when I have given a description of the structure of the two systems of organs now adverted to. The hepatic tubes in the Blow-fly (*Musca vomitoria*) for a considerable part of their course present remarkable dilatations and constrictions; these are sometimes situated so as to face each other on opposite sides of the tube, at other parts they are placed more nearly alternate. Towards its commencement each tube is found to consist of a number of vesicles, which are arranged in a series so as to overlap each other; these vesicles are more or less perfectly fused together, their coalescence becoming more complete, and the margin more even as we advance towards the intestinal extremity of the tube. In many insects the walls of the tubes are perfectly even and present no bulgings or constrictions; even the terminal blind extremity is, I think, for the most part undilated. A most distinct and strongly-marked basement membrane, unsupported by any fibrous tissue, but often covered by minute ramifications of tracheæ, constitute the wall of the tubes; it is perfectly homogeneous, but presents nothing that I have ever seen corresponding to the germinal centres of Mr. GOODSIR. On the interior of the basement membrane is a layer of granular matter of variable thickness; this is often of a deep yellow tint from the presence of biliary matter, or rendered opake for a greater or less extent by deposits of oily matter; in it are imbedded cells which are sometimes granular, and exhibit traces of nuclei, especially I think in their early stage, but mostly appear as large, delicate and quite transparent vesicles, which often escape from their bed of granular matter, and collect in the central canal, along which they glide rapidly when subjected to some degree of pressure; the diameter of these varies from $\frac{1}{1500}$ to $\frac{1}{600}$ th of an inch; they are particularly remarkable from the circumstance that the secretion does not form *in* them, but under their influence probably in the surrounding granular matter. In most instances the layer of granular matter is of the same appearance in its whole thickness, but occasionally I have noticed that the stratum in contact with the homogeneous tunic was quite pale, while that bounding the central canal was more or less deeply tinged with yellow,—an interesting difference, which would seem to indicate a gradual evolution of the

material of the secretion from a previously formed granular blastema. The contents of the tubes are for the most part free in the cavity, and form a continuous layer along the wall; but sometimes, especially in the sacculated tubes of the fly, the cells and granular matter form separate masses, though these are not I think surrounded by envelopes*. The central canal varies much in width; sometimes it is very narrow or obstructed with oily or biliary matter, in other cases it is equal to half the diameter of the tube.

Directing our attention now to the so-called adipose tissue, which I will venture to name the parenchymal portion of the liver, it is to be observed that it varies a good deal both in its extent and in its general appearance in different instances; moreover, it is not always uniform throughout, but presents in different parts successive stages of development. In its simplest and primary state, it appears as a pale, granular and amorphous blastema, containing numerous large cells, the average diameter of which is $\frac{1}{750}$ th of an inch; these are provided with a distinct envelope enclosing well-formed nuclei and granular matter of a yellowish tinge. Very numerous young cells are also present in the blastema; they are nucleated, and contain only pale granular matter; their diameter varies from $\frac{1}{3-2000}$ of an inch: lastly, oil-globules of a greenish yellow tinge, some large and others of minute size grouped together, are also found in this material; these seem clearly to arise from the blastema and not to be produced in cells, in which they are never found. Following on now the development of the parenchyma, we find that a mass of granular blastema, in which lie both young and fully-formed cells, assumes a definite form, its margin becomes even and invested by an homogeneous membrane; thus we have produced vesicles, or short tubes of various size and shape, which coalesce very irregularly with each other, and form a kind of coarse net-work. Occasionally the vesicles are found free and unconnected with others; sometimes also they are replaced more or less completely by long tubes, which might easily be mistaken for the hepatic tubes themselves. The contents of the vesicles or tubes vary a good deal; in Caterpillars they are wholly filled with large colourless oil-drops; in Butterflies, Maybugs, and some other insects, they contain a quantity of yellow biliary-looking matter, with various proportions of oily and granular matter. In some cases there is scarce any oily matter at all, but only granular, pale, or of a yellow tint. The primary cells may almost always be discerned in the interior of the vesicles, and upon them doubtless depend the persistent action of these structures. The interesting observation of Dr. WILLIAMS, respecting the termination of minute tracheary ramifications in the vesicles of moths and butterflies, I have been able in some measure to confirm: I cannot speak positively as to the tracheæ actually terminating in the vesicles, but I have seen them traversing an elongated vesicle from one end to the other, and thus holding nearly as intimate a relation to the contents as if they had actually terminated in them.

* Dr. WILLIAMS describes, as the constant arrangement of the contents of the tubes, large cells containing several secondary ones with granular and biliary matter.

As reasons for considering the tissue now described as part of the hepatic apparatus, I may mention,—1st, the close resemblance which often exists between the contents of the vesicles and those of the undoubted biliary tubes; in several instances, in fact, they have appeared to me identical. 2nd. The presence of distinctly yellow fluid, either infiltrating the granular contents of the vesicles, or united to oil-drops: this fluid may be reasonably supposed to be of the nature of bile. 3rd. The existence of much granular matter, shown by chemical tests to be of albuminous nature, of granular cells and nuclei in the vesicles, shows that they cannot be regarded as adipose tissue merely; nor should we expect to find this in such constancy and abundance in a class no higher than that of Insects. 4th. The oily matter which is found in them is usually not at all more abundant than in the liver of many higher animals; it exists also in a state of diffusion and combination with the granular matter, and its presence (since the tissue is surely not mere adipose) argues in some measure in favour of its hepatic character, it being well known how prone oily matter is to accumulate in hepatic structure. Were it proved by chemical tests that the yellow fluid, not unfrequently seen in the vesicles, is truly bile, no further argument would be needed; of this however I have been unable to obtain positive evidence; yet once I observed the yellow tint to be decidedly deepened by nitric acid, and from the action of this reagent and sulphuric acid in other instances, I am pretty well satisfied that albumen and oily matter are not the only contents of the vesicles.

The above arguments, though far from conclusive in favour of the opinion I have adopted, are not without weight; and I will only add, that if this view should prove correct, an analogy will obtain between the hepatic apparatus of the Leech and that now described as existing in Insects.

The structure of the liver in Crustaceans is so well known, and has been so well described, that I can add nothing to our knowledge respecting it; I would remark, however, that the large quantity of free oily matter which is found in the follicles of this class, must be regarded as an indication both of the feeble intensity of the respiratory process, and also that the secretion is not to be regarded as in any great degree excrementitious, since it would not then be found accumulating in such quantity. Before passing on, however, I must particularly allude to one interesting individual which is ranked with this class, the *Daphnia monoculus*: this little creature, from the transparency of its shell, and the simplicity of its organization, is a most favourable object for examination. Any one who would study the phenomena of muscular action in the living fibre to advantage, should not omit to examine a living specimen of this species; striped fibres exist in the larger ones, and the oscillating waves of contraction during the action of the fibre may be distinctly observed. The hepatic apparatus in the *Daphnia* I believe to consist of large cells whose diameter is about $\frac{1}{7-500}$ th of an inch; these are chiefly aggregated round the intestine, but exist also in other parts; they have a distinct envelope, which encloses a transparent fluid and a large reddish yellow oil-drop, with one or two smaller ones; a nucleus is

sometimes discernible, especially when the secretion is in small quantity. These cells usually cohere together, yet retaining perfectly their separate outline; but sometimes the groups seem to become fused together, and to form a mass which is applied against the intestinal wall by a covering membrane. It seems quite certain that these cells are naked, and uncontained in any follicular offsets from the intestine; nor does there appear to be any provision for the transmission of the secretion thither; that they perform the function of a liver is I think highly probable; their appearance is generally such that one can scarcely hesitate to believe them to be agents of biliary secretion, and I cannot find any other apparatus which seems at all adapted to fulfill such an office. However, I must state that in some cases, especially when the *Daphnia* is laden with ova, these cells are almost devoid of their biliary-looking contents, and are much less manifest, though even then themselves or their nuclei are discernible more or less clearly. Still, as it is impossible to believe that they can be merely adipose tissue, I regard them as of hepatic nature, and would refer to them as an interesting example of a purely parenchymal hepatic organ.

As a specimen of the liver among Arachnidans, I believe that of the common house spider may be referred to; here the liver is very bulky indeed, occupying the greater part of the pouch-like abdomen; it is of a dull yellowish-white colour. In structure it consists of short cæcal follicles very closely set together, about $\frac{1}{84}$ th of an inch in diameter; each of these is bounded by a well-marked limiting membrane, and stuffed with opaque contents. The cells in the interior of the follicles measure about $\frac{1}{650}$ th to $\frac{1}{800}$ th of an inch; they have a very delicate envelope, and contain a quantity of opaque oily-looking matter, with one or more granular but highly refracting vesicles; these are usually $\frac{1}{3-2000}$ th of an inch in diameter, and appear subsequently, when set free, to undergo development into secreting cells. There is a good deal of free oily matter, but very little trace of bile pigment; the oily matter very often appears in the form of groups of small equal-sized vesicles $\frac{1}{6-5000}$ th of an inch diameter, which almost seem to be enclosed in a definite envelope; this may be the commencement of the formation of nuclei or young cells under the favouring physical conditions which ASCHERSON has pointed out. The large size of the gland in this class is worth noticing, as well as the character of its contents, which consist principally of granular and oily matter.

Among the various families of the Mollusca, the follicular type of arrangement of the liver obtains, I believe, universally; the gland is remarkable in most cases for its large size, and frequently for the deep colour of its elaborated contents. In most cases the basement membrane of the follicles is extremely distinct, but occasionally it is very delicate, and even its existence has sometimes appeared to me doubtful; this led me originally to believe that the presence of the basement membrane was not essential to the act of secretion, but that its function was of a purely mechanical nature, supporting the secreting cells, and preserving constantly a passage to the excretory duct. Subsequent observations have quite confirmed this opinion, by

acquainting me with several instances where it is certainly absent from glandular structure; thus, in the pancreas of a pigeon, I recently ascertained the total absence of limitary membrane from the ultimate vesicles, the epithelium being arranged into follicle-shaped masses and tubes, the form of which was solely preserved by the cohesion of the particles together. In the Common Oyster (*Ostrea*) I noticed a similar instance; here, besides the well-known follicular liver, there is a thin lamella of reddish brown aspect, which lies between the mass of the liver and ovary and the adductor muscle in contact with the intestine, to which it adheres pretty firmly. In structure this consists of numerous cells aggregated together, and set as it were in an imperfectly fibrous tissue; these cells measure about $\frac{1}{1500}$ th of an inch diameter, and are provided with an envelope enclosing biliary-looking granules, which sometimes fill them completely: nuclei are rarely to be seen in them, but free nuclei and young cells occur in the uniting tissue. Now these cells, which seem to belong to the hepatic apparatus, from the nature of their contents, are certainly not contained in follicles or any envelopes of limitary membrane, but lying interstitially fulfill without doubt a work of secretion. This view of the non-essentiality of the basement tissue was promulgated some years ago by the distinguished physiologist who gave the membrane its name and pointed out its wide-spread extent. To illustrate a condition of the liver not uncommon among Mollusca, I may mention the examination of a Fresh-water Snail (*Limnæus stagnalis*), which I made during the cold spring of last year; the organ was of very dark aspect and soft consistence, and its basement tissue was scarcely discernible; the secreting structure consisted of a large quantity of amorphous and biliary matter in a free state, with numerous cells, some of which exhibited an envelope, an interior nucleus, and granular or biliary contents; others were merely pale granular bodies: these cells seem to originate as delicate vesicles having a mean diameter of $\frac{1}{2000}$ th of an inch; they acquire pale granular contents, and probably, at some period of their existence, nuclei; but from observation of this and several others of the lower animals, it has seemed difficult to believe that the energy of the cell is always dependent on the presence of a nucleus. In the higher animals I think this is certainly the case, and yet there would appear even in them to be an exception in the fat cells, which vary so much in size, that it seems certain their growth must continue long after the disappearance of the nucleus. A circumstance which was very striking in the examination of the liver of the *Limnæus*, was the prodigious quantity of dark biliary matter which was accumulated in it; in many parts it seemed as if the follicle-shaped masses were perfectly solid, converted, one might almost say, into biliary calculi. This state of the secreting apparatus must surely be conceived to imply a very tardy and imperfect discharge of the elaborated matter, and accords well with the imperfect character of the respiratory process. In a *Sepia*, one of the most highly organized among the Mollusca, the liver was still found to be of the follicular type; the terminal cavities were however very short and wide, and the limitary membrane by no means conspicuous: the contents were of

the usual kind, nuclei, cells, and abundant granular and oily matter, with some yellow masses which seemed to consist of concrete biliary substance.

In concluding this imperfect survey of the structure of the liver in the Invertebrate sub-kingdom, we may recapitulate by observing, that the tubular or follicular type of arrangement is that which generally prevails, and to which a tendency is almost invariably manifested; yet it has been shown to be probable in several instances, that a more or less considerable portion of the gland is in a condition which may be termed parenchymatous, the secreting structure being interstitially situated and not in connection with any excretory duct. In the next great division of animals at which we arrive, the hepatic apparatus is constantly distinguishable into a tubular and parenchymatous portion, but the latter now preponderates immensely, and the office of the tubular structure is confined to serving as an excretory duct; the evidence of this will clearly appear in the class of Fishes, which will next be investigated.

With the exception of the curious Lancelet (*Amphioxus*), the liver in all fishes may be stated, on the authority of Professor Owen, to be a parenchymatoid organ, provided with efferent hepatic ducts, and usually a gall-bladder and cystic duct, which pour the secretion into the duodenum. The blood-vessels entering the liver are now of different kinds, the portal vein or veins supplying altogether the parenchyma, while the hepatic artery is devoted principally to the ducts: this circumstance I think has not yet been fully accounted for; it will again attract our attention when we consider the manner in which the secretion is conveyed into the excretory ducts. Respecting the actual structure of the liver in Fishes, as in all Vertebrate animals, our knowledge has hitherto been very imperfect; for though, if I may use the term, the geography of the organ was perfectly set forth by Mr. KIERNAN, yet since we have become acquainted with the actual agents in the process of secretion, the cells which elaborate the bile, and which constitute so very large a part of the organ, it has remained a complete mystery how the ultimate bile ducts were disposed with relation to the cells, and in what manner the secretion when formed was conveyed into the excretory passages. Before giving an account of the observations I have lately made respecting these points, I ought perhaps to mention that, according to Dr. WILLIAMS, the structural arrangement in fishes is nearly the same as in the molluscous tribes, the secreting cells being enclosed (he deems) in tubes of homogeneous membrane; this, however, is so completely contradicted by all that I have seen, that I shall do no more than thus cursorily allude to it. As it appears to me that in Fishes, the lowest of the Vertebrate classes, we find the liver at once assuming a very different type of arrangement from any which it has hitherto exhibited during our survey of the animal series, it is evidently a matter of great importance to determine, if possible, its real constitution, and to understand in what the essential change consists which has produced so marked a difference of form and character; fortunately this is rendered more practicable by the circumstance, that in the liver of fishes there is comparatively a small quantity of fibrous tissue (corresponding to the capsule of Glisson) diffused throughout

the gland, which therefore separates much more readily into its elementary parts: I have endeavoured to take advantage of this peculiarity to ascertain the actual condition of the ultimate hepatic ducts, and I trust that I have in some measure succeeded. Taking up a main branch of the duct, I find that by gentle traction and lacerating the surrounding parenchyma, I can isolate it with a multitude of ramifications without much difficulty, and after gentle washing remove it to a slip of glass. When now the specimen is spread out, and covered with a thin lamina, it can be conveniently examined: some of the branches, especially the larger ones, are evidently broken across, but a great number of the smaller ramifications do not appear to have suffered injury, and their characters may be thus described. They have a diameter of $\frac{1}{1000}$ — $\frac{1}{500}$ th of an inch at their origin from the trunks; they run a remarkably long course, giving off very few branches, and those for the most part at long intervals, though sometimes a group of minute branches arise close together; they taper slowly towards their extremities, which are found in various conditions, sometimes undoubtedly closed, with a defined rounded margin formed by homogeneous membrane; this however is rare; more usually the structure towards the extremity becomes less distinct, and it seems as if the duct gradually ceased. The larger ducts and the smaller at their commencement are invested by a thin layer of fibrous tissue; within this is a distinct basement membrane, which extends beyond the fibrous layer for a variable distance; sometimes it forms the rounded closed extremity of the duct, but mostly it becomes gradually faint, and can only be supposed to exist by the duct still exhibiting a well-defined margin; in many instances it certainly ceases some way from the terminal extremity. The contents of the ducts vary considerably; in the larger ones there may be either nuclei with granular matter forming an epithelial layer, or very delicate and pellucid vesicles; or the cavity may appear transparent, containing only some finely-mottled substance. Advancing to the smaller ducts, we find that they may likewise contain pellucid vesicles, so large as to occupy their whole cavity, but more frequently they are filled with nuclear granules and granular matter, the nuclei again being often very indistinct, so that there is scarce anything but granular matter to be detected; when they are in this condition the basement membrane also has generally disappeared, and the aspect of the duct, some way before its termination, is that of a tract of granular matter, which preserves accurately the tapering form and course of the original structure. In some cases the fibrous coat is prolonged further than usual, being continued as a filamentous expansion into the surrounding parenchyma beyond the terminal extremity of the duct. The foregoing description expresses the results at which I have arrived from numerous dissections of the liver in marine fishes; in the Perch (*Perca*), however, I have observed a condition of the ultimate ducts which differs from that now described in some respects, but resembles exactly that which is found in the mammalian liver; instead of appearing as minute cylinders of granular matter in which nuclei are scarcely perceptible, these ducts consist almost wholly of small nuclei set close together in a

scanty basis substance; they are quite devoid of basement membrane, and measure only $\frac{1}{5-3000}$ th of an inch towards their terminal extremity. The mode which I have adopted of examining the ducts may be thought by some to be objectionable, on the ground that the extremities of the ducts must necessarily be lacerated; but I think a careful repetition of the process I have indicated, will satisfy the observer that it offers the most probable means for deciding the point in question; in fact I know of no other except injection which can be adopted, and I am satisfied that in this case the results of injection are not to be depended on. To one remarkable character of the ducts which has been mentioned I would ask especial attention, viz. the long course which the smaller ramifications take without giving off branches. I have observed one which ran $\frac{1}{50}$ th of an inch without giving off any branches, and another which gave off only one branch in a course of $\frac{1}{20}$ th of an inch. When we take into consideration this fact, and remember also how minute the terminal extremities of the ducts become, and that they are not unfrequently seen distinctly closed, it will appear quite certain that the ducts can have no actual connection with the surrounding parenchyma, so as to envelope and contain it in their terminal expansions, as some have supposed. The real relation of the ducts to the parenchyma is, I think, well shown by a peculiarity in their condition which I have noticed as of tolerably frequent occurrence; when this exists there are found in the parenchyma numerous masses of more or less deep biliary tinge, consisting apparently of large yellow granules enclosed in an envelope; when a duct is dissected out, these yellow masses are found adhering to it at various parts of its circumference; they are manifestly not in the cavity of the duct, but simply adherent to it. That these yellow masses originate in the secreting parenchyma is I think indubitable; they evidently consist of biliary matter; but this seems to have undergone some change, which has rendered it incapable of being readily absorbed by the ducts, and it thus remains on the exterior, indicating as it were the route it would normally pursue. I may here describe some remarkable structures which I have found in the liver of the Skate (*Raia Batis*), and respecting which I am rather in doubt whether they belong to the parenchyma or the ducts; these are vesicles of oval or subcircular form, measuring from $\frac{1}{750}$ to $\frac{1}{330}$ th of an inch in diameter; they have a distinct envelope of homogeneous membrane, and a central cavity, which does not occupy more than half the diameter of the vesicle; the intervening substance between the wall and the cavity presents no distinct structure, but only some traces of concentric layers with a few nuclear corpuscles; the aspect of the vesicles is such as to imply that they are filled with some substance having a high refractive power, which is probably of oily nature, derived from that which is so abundantly diffused throughout the parenchyma. These vesicles are often found free, and unconnected with any other structures; they appear to be scattered throughout the parenchyma, but are sometimes at least involved in the fibrous sheaths of the ducts, so as to remain adherent to them; what their function may be is quite hypothetical; I can only conjecture that they may serve as reser-

voirs in part for the immense quantity of oily matter which is produced in the gland.

Turning now to the examination of the parenchyma of the liver in Fishes, it may be stated that it does not usually present a very marked division into lobules; this however is often indicated by the branching of the vessels, which do not run in interlobular fissures, such as exist in the liver of mammals. The term parenchyma is in the greater number of instances exactly expressive of the condition of the secreting portion of the hepatic apparatus in fishes, it is truly a substance poured among and upon the vessels and ducts, filling up completely the interstices between them, and forming together with them a solid mass: its actual state may vary a good deal; sometimes the greater part consists of perfect cells with distinct envelopes, and there is only a small quantity of free nuclei with granular and oily matter; at other times these are found to predominate, and but few perfect cells are to be detected; in this case however we very commonly observe a tendency to the formation of cells, the granular and oily matter being aggregated into cell-like masses, which either enclose or have enclosed at some time a nucleus. The masses of biliary granules, which I have already mentioned as adhering to the ducts, occur also free in the parenchyma; besides these, I have found in the Mackerel (*Scombrus Scomber*), and also in the Flounder (*Platessa flesus*), some peculiar cells which are perhaps of the same nature as the above-mentioned masses; they are larger than the secreting cells, of a perfectly circular form, and contain, within a well-marked envelope, from three to five oval or subcircular vesicles, which have often a nucleolar corpuscle in their centre, and possess a high refractive power; these cells lie free in the midst of the parenchyma, often forming small groups, which are imbedded in yellowish granular matter. The Flounder furnishes an exception in some measure to the rule, that the liver of fishes is not divided into lobules by fissures; the last twigs of the portal vein may be distinctly traced running in canals and short fissures in thin sections of the organ, these canals being much wider than the vessels contained in them; hence arises in certain conditions of the gland a remarkable disposition which is well worthy of notice. I have usually found the parenchyma of the liver in this fish of a yellowish white colour, and very opaque from the great quantity of oily matter contained in it; but sometimes it is found much more transparent and of a redder tinge; in the former of these conditions the canals and fissures are comparatively empty, but in the latter they are filled with cells of about the same size as those of the parenchyma, but more opaque and of a darker aspect from the oily nature of their contents. The interpretation which I would offer of this appearance is, that in this state the parietal cells of the canals and fissures do not readily dehisce and discharge their contents into the cavity, from whence they may be absorbed by the excretory ducts, but encroach upon and fill it up: we shall find in Mammalia instances of a somewhat similar occurrence, which appear to me particularly significant of the real constitution of the liver.

An important circumstance which cannot but arrest the attention in examining the livers of many fishes, especially those of the Skate and Cod, is the very large amount of oily matter which is manifestly in a free state; this, as we have on former occasions remarked, indicates a low intensity of the respiratory process, and also serves as a further proof of the correctness of the view here taken of the structure of the liver; for were this abundant oily matter free in the cavities of ducts, it should surely constitute in great part the contents of the gall-bladder, and so marked a difference would not exist between the dark-green fluid found in that receptacle, and the dead white of the adjacent parenchyma of the liver. Doubtless the excretory ducts separate, by a process of vital absorption, the bile from the oily matter in which they are bathed.

Among Reptiles I have examined the Common Snake (*Coluber natrix*), the Fresh-water Tortoise (*Emys europæa*), the Turtle (*Chelonia mydas*), the Newt (*Triton cristatus*), the Frog (*Rana temporaria*) and the Toad (*Bufo vulgaris*); in all these the liver is, *κατ' ἑξοχὴν*, a solid gland, the capillary network extending equally in every direction: the coats of the capillaries are remarkably strong, and there can be no better opportunity than is here presented for examining their structure, which corresponds pretty closely with that figured by HENLE. In most of these animals I have examined the ducts by dissecting them out in the way I have described, but by no means with such satisfactory results as I have obtained in fishes; this depends on the greater strength of the fibrous and other tissues composing the framework of the gland; however, in the Newt, Snake and Toad, I have been able to determine sufficient respecting the ducts, to satisfy me that they do not differ in any essential circumstance of structure or arrangement from those of fishes: thus it is quite certain that they bear only a small proportion to the mass of secreting parenchyma; they can be traced running a long course through it, and giving off very few branches, and in one or two instances they have clearly been seen to terminate by closed extremities. In structure they consist of a delicate epithelium with an investing layer of basement membrane, and often of fibrous tissue; these latter elements are often wanting in the smaller ducts, whose diameter varies from $\frac{1}{3}$ to $\frac{1}{1000}$ th of an inch; towards their terminal extremity also the tubular character is often completely lost, and the nuclei become indistinct, so that there remains only a tract of granulo-amorphous matter containing some minute oil-drops, which is soon lost in the surrounding parenchyma. This mode of termination in reptiles, as well as in fishes, is manifestly equivalent to terminating by a closed cæcal extremity, as far as regards a direct communication with the secreting parenchyma.

In none of the Reptilia that I have examined has there appeared any manifest tendency to a division of the parenchyma into lobules; it consists of delicate cells, free nuclei and granular, with a small proportion of oily matter: in the Snake these are arranged into masses of a definite form, which are disposed so as to represent short linear series coalescing to form a plexus, but in the others they merely occupy

and fill the interstices of the capillary network. Sometimes, as in the Toad and Snake, the greater part of the secreting structure is in the form of free nuclei and granular matter, with globules of secretion; in others, as the Tortoise, Frog and Newt, the perfect cells are more abundant; these are usually very delicate, appearing often like transparent spaces in the midst of the darker surrounding substance. Besides these, the ordinary elements of secreting structure, there are constantly found in all the animals I have mentioned, excepting the Snake, a great number of rather large dark yellowish corpuscles imbedded in the parenchyma; these in the Eft measured from $\frac{1}{1700}$ to $\frac{1}{250}$ th of an inch; their form is usually circular or rather oval, but sometimes irregular when several have coalesced together; their margin is generally well-defined, they lie quite separate and unconnected with any other structures. I have not been able to determine exactly the mode of their production; sometimes it has appeared that a number of dark yellow granules were grouping themselves together to form a circular mass; they exhibited very active molecular motion, but were enclosed by no envelope; in other instances a delicate envelope is distinctly demonstrable, and once I have observed a mass of similar granules enclosed in a cell with envelope and nucleus. It seems on the whole probable that these dark corpuscles are produced in some way by the agency of cells, or perhaps by their nuclei alone, and it is scarcely doubtful that they must be considered as products of hepatic secretion, though an eminent chemist, whom I requested to examine them, was unable to discover in them the usual reactions of bile. These remarkable biliary concretions (for so I think we may call them), occurring in the liver of reptiles, are evidently identical in their nature and import with the yellow masses described in the liver of fishes; both are doubtless indications of imperfect excretory action; but the deep, almost black colour of the retained product in the reptile, and the great deficiency of oily matters in the gland, as compared with that of the fish, seem to lead to the conclusion, that a vicarious relation subsists between the colouring and fatty principles of the hepatic secretion; and this is borne out by the appearance which is presented in complete fatty degeneration of the human liver, compared with the same in a state of biliary congestion, the olive tint of the latter condition being replaced by the dull yellowish white of the former.

In Birds the liver is of a crisper texture, and much lighter colour than in most reptiles; it presents decided indications of a lobular arrangement, and in thin sections portal canals may be easily traced dividing into fissures. Its parenchyma varies in character; in a pigeon it was remarkably free from oil-globules, and consisted almost entirely of nuclei and granular matter, no perfect cells being discernible; in a swan (*Cygnus olor*) the secreting substance was of a dark greenish colour, owing to the presence of biliary matter, and chiefly disposed so as to form masses having a plexiform arrangement; in a duck (*Anas boschus*) the parenchyma was equally destitute of perfect cells, consisting entirely of nuclei and granular matter, with diffused oily particles; there were also numerous groups, as well as separate molecules of biliary matter, lying free in the parenchyma, and also in the fissures by which it was traversed.

These and several of the observations previously recorded render it, I think, certain that the formation of perfect cells is not necessary to the act of secretion, the nuclei alone are, doubtless, adequate to produce the necessary change in the exuded plasma; but if it be intended that the structure shall have a certain degree of permanence, then it is surrounded with an envelope, to isolate and confine in some measure the elaborated contents.

In the Pigeon, the ducts, when dissected out, were found to terminate very much in the same manner as they do in the liver of mammals; thus one small branch, $\frac{1}{1000}$ th of an inch in diameter, appeared to terminate by a closed extremity; its walls consisted of nuclei set close together in an amorphous or finely granular basis-substance, and were not invested by any basement membrane; another branch, $\frac{1}{1000}$ th of an inch in diameter, was seen in one part of its course to have a fine homogeneous tunic enclosing nuclei and granular matter; it terminated by losing its tubular character, and becoming resolved into a tract of very perfect and beautiful nuclei, which still retained the original form of the duct. In an owl I found one or two minute ducts which certainly seemed to terminate by closed extremities; they consisted principally of a finely granular substance containing small greenish yellow oil-drops; nuclei were seldom visible in them, and the basement membrane ceased before their terminal extremity. In an examination of a duck I obtained some very perfect specimens of the ultimate ducts; they were often long and slender, about $\frac{1}{3000}$ th of an inch in diameter, and tapered very gradually to their extremity, which I think was in some instances certainly closed. In structure they resembled pretty nearly those of the Owl, appearing as cylindrical tracts of granular matter, but the nuclei in them were rather more distinct; in one of them which I have figured it is well seen how the basement tissue, distinct at one part, gradually fades away, and is lost as the duct diminishes toward its terminal extremity. From these observations there can be no doubt that the liver in birds is of the same type of structure as that which we have found to prevail in the two lower Vertebrate classes; we may remark again, in these animals of rapid circulation and active respiration, how the character of the oxidizing process affects the condition of the liver, a very small quantity of oily matter only existing in the parenchyma of the Pigeon, a bird of vigorous flight, while that of the stately and slow-moving Swan presents evident traces of retained secretion.

Lastly, we arrive at the Mammalia, in whom each of the glandular organs has a definite and unvarying type of structural arrangement. The tubes of the testis and kidney, the vesicles of the salivary and allied glands, are familiar to our thoughts and observations, but the well-defined and closely-crowded cells of the liver are yet scarcely acknowledged to constitute a parenchyma in the true acceptation of the word, several yet seeming to incline to the belief that they are contained in some way in terminal expansions of the ducts. In endeavouring to determine the long-mooted question, as to the mode in which the biliary ducts terminate, I have of course resorted to the method of injection, but except in the case of the Pig, I cannot think

that I have obtained any satisfactory results; a better prospect of success is I believe afforded by the mode of examination I have already described, in which actual recognition of structure, and not appearance only, is accepted as decisive evidence of the presence of the duct. Before proceeding to describe the results of my dissections of the ducts, I may state what appears to me to be an unexceptionable conclusion drawn from injection of the hepatic ducts in the Fig. Here, when a successful injection has been made in the double mode so successfully employed by Mr. BOWMAN, the lobules are seen to be definitely marked out by yellow lines or tracts, corresponding to and exactly occupying the "fissures" and "spaces." In several beautiful specimens thus prepared, the yellow line presents a most defined edge, and does not trench in the slightest degree upon the interior of the lobule; from this I cannot but conclude that no tubular duct penetrates the secreting structure; for were such the case, it is impossible that the injection should not, to some extent at least, have coloured the substance of the lobule. Hitherto I believe no particular description has been given of the structure of the minute branches of the hepatic duct; the larger ones are known to have a columnar epithelium resting on a subjacent basement membrane, which is strengthened by an investing layer of fibrous tissue. In the minute branches, which seem to be approaching their termination, and which sometimes can be isolated and examined in the most satisfactory manner, the epithelial particles are remarkably modified; they can scarcely be said to exist as separate individuals, but rather their nuclei, which are often large and distinct, are set close together in a subgranular or homogeneous basis-substance. In ducts where this condition of epithelium exists, there is seldom any distinct trace of basement membrane, the margin, though sufficiently even, yet exhibiting the bulging outlines of the component nuclei; still less is there any proper fibrous coat, though the ducts may be more or less involved in the filamentary expansions of the capsule of GLISSON. Ducts of this character have usually a diameter of about $\frac{1}{1000}$ th of an inch; they can be sometimes followed for a considerable distance, without being seen to give off any branches, or to diminish much in calibre. Their mode of termination is various; several have been distinctly seen to terminate by rounded and closed extremities, which have nearly the same diameter as the duct itself; others seem to lose their tubular character, their nuclei become less closely set together, and the uniting substance more faintly granular and indefinite; the duct in short gradually ceases, losing all determinate structure. In some of rather minute size, $\frac{1}{3-2000}$ th of an inch in diameter, the exterior form remains distinct, but the canal is almost obliterated by the close approximation of the nuclei of the opposite walls. These structures now described I believe to be truly the terminal branches of the hepatic duct, from which they certainly originate; they seem gradually to lay aside the several component tissues of the larger ducts, the fibrous coat blending with the ramifications of GLISSON'S capsule, the basement membrane imperceptibly ceasing, and the epithelium being resolved at last into its simple fundamental nuclei. The above account has been taken chiefly from examination of

the liver of the Sheep, but in the Human subject and in the Pig I have made observations precisely similar.

In proceeding next to speak of the parenchyma of the liver in Mammals, I must recur to some points which I have dwelt on in a previous paper; several of these have been fully confirmed by my later observations, but in respect to one I have fallen into a considerable error. I described (as Mr. BOWMAN had previously done) the cells composing the lobules as arranged in long radiating series around the interlobular vein, the series however communicating with each other, and presenting a more or less decidedly plexiform arrangement: I observed the sides of the lobules to be invested by a membrane, which was continued across the floor of the fissure to line the side of the opposite lobule; this membrane, in the Rabbit and often in the Sheep, is truly homogeneous, and resembles exactly the basement tissue. I concluded it to be such, and believed that its presence afforded exact information of the mode in which the excretory duct terminated, which would thus appear to have expanded into the interlobular fissure. This view was further confirmed by the observation that the supposed basement membrane was often deficient, the marginal cells of the lobules being then irregularly prominent, and crowded with secretion globules, which appeared to be escaping in great numbers into the interlobular fissure. Subsequent examination has convinced me that the membrane investing the lobules is not really the basement tissue of the ducts, but a continuation of the capsule of GLISSON; that however it is frequently of homogeneous texture, that it is also often absent, and that the marginal cells are then in the condition which may be termed active, are points which repeated examination has fully confirmed. Respecting the office of the interlobular fissure as a receptacle of the secretion, and *pro tanto* a portion of the duct, I hardly feel able to make confidently a general statement; it certainly is often seen crowded with globules of secretion, which have evidently been produced by the marginal cells of the lobules; at other times it appears empty, and the sides of the lobules are evenly lined by the investing membrane; not unfrequently (at least in the Sheep) the interlobular "fissure" has completely disappeared, and even the "space" become contracted, from the encroachment of the peripheral cells of the lobules, so that the mammalian liver has then assumed pretty nearly the condition of the undivided liver of Fishes:—a conclusion probably not far from the truth is, that the fissure may often serve as a receptacle for the secreted product, especially when the gland is in a high state of activity, but that under ordinary circumstances the removal of the secreted bile may be effected without its having been first received into the fissure. I may here record an observation which I made on the liver of a dog who died of granular disease of the kidneys. On the surface of a section of the organ there were seen a number of yellow ramifying lines or tracts, which were found to be occasioned by the accumulation of a quantity of yellowish material in the portal canals and fissures; this deposit undoubtedly was in part of biliary nature, and seemed to indicate that the absorbing action of the excretory ducts having been

checked, the secretion from the marginal cells of the lobules had accumulated in the fissures and canals, so as to produce the appearance described. Now that, which occurred to an extreme degree in this abnormal condition, may very probably take place to a lesser extent when the gland is in a healthy state, and there would seem in all cases to be a tendency to the occurrence of something similar. The theory, first suggested by HENLE though not adopted by him, which I endeavoured to establish in my previous paper, respecting the mode in which the bile, elaborated by the cells in the interior of the lobule, is conveyed to the efferent duct on the exterior, viz. that it makes its way by transmission from cell to cell of a linear series, is I think somewhat confirmed by what I have occasionally observed respecting the disposition of the contents of the cells when arranged in a series; thus in one very perfect series of some considerable length, there was a distinct indication of a central canal extending throughout it, the granular matter in each lay in contact with the cell-wall, and the middle part of the cell was comparatively free. But though from the examination of certain livers we might be led to conclude that this mode of transmission was the only one in which the secretion of the cells was disposed of, yet instances are abundantly frequent which render it very probable that there is another and more direct mode in which the removal of the cell product, prone as it is to accumulate, is provided for. Now the following circumstance cannot I think but arrest the attention of all who are in the habit of examining the condition of hepatic structure, viz. that the quantity of *free* oily (perhaps also of biliary) matter varies very greatly; sometimes it is extremely abundant, at others scarce any is to be found: moreover it is manifest, that the product of secretion, while thus freely diffused, is just in the condition which renders it most exposed to the absorbing action of the circulating current. If the materials which serve as fuel for respiration are deficient in the blood, they may be readily absorbed into this fluid, as it percolates the lobular masses; and we may go further, and state that it is quite probable, that even while the biliary secretion is contained within the cell envelope, it is capable of being influenced by the state of the blood, so as to make its way by endosmosis, into the capillary streams, through the homogeneous membranes of the cell and blood-vessel. This view will not seem improbable, if we reflect on the simple constitution of the lobules, where a vast mass of naked cells is traversed by an exceedingly close capillary network; the cells and the blood are therefore brought into the closest relation possible, and it cannot but be on mere physical principles, that the contents of either should tend to intermingle. I may also remark, that this view supplies another reason besides that suggested by Mr. SIMON for the absence of the basement membrane, viz. that not only the cells may be more freely exposed to the blood, but the blood also to the contents of the cells. The above suggestions, founded on structural characters, and on the varying conditions of the organ, harmonize well with the view which has lately received so much support from chemical inquiry, and which regards the bile as mainly intended to be absorbed and returned to the circulation; they may also help to explain why the bile has to pursue so tardy and indirect a course

before it can be received into the excretory duct ; and lastly, if correct, they seem to establish that the liver is not widely removed from the class of glands destitute of efferent ducts, like them allowing a part of its elaborated products to return at once into the blood, from whence as plasma they had been derived. On a future occasion I trust to have the opportunity of examining more closely into the function of the liver. I may however at present remark, that if the capillary radicles of the portal vein absorb the saccharine and amylaceous matters from the intestines, it seems a wise provision that the blood so charged should percolate intimately a vast mass of cells, which may specially act on the newly-absorbed materials, retain them if they are in excess, convert them into biliary compounds, and again allow them to return, as needed, into the circulating current: this in fact is nearly the view proposed by Messrs. BOUCHARDAT and SANDRAS. I have, lastly, to speak of the relation which the excretory ducts, before described, hold to the lobules of the parenchyma. As far as I can ascertain, they do not ramify very extensively, at least both in the Rabbit and Sheep many fissures appear quite destitute of them ; in those where the margin is in an active state, the cells bare and discharging their contents, the absence of the duct may often I think be clearly determined ; in others, where the margin is still covered by the investing membrane, it is more difficult to be certain, but generally I think it may be stated that they do not extend far beyond the "spaces;" here however I have in thin sections several times distinctly observed small ducts which terminated by closed extremities. In the portal canals small duct branches creep over the surface of the parietal lobules, and take up their elaborated products. In now endeavouring to determine the mode in which the biliary secretion formed exterior to the ducts arrives in their interior, we may recall with advantage the condition of the gland, as we found it to exist in the class of Fishes. Here it was seen that the excretory ducts, having coats of great tenuity and containing an active epithelium in their interior, ran a long course imbedded in the parenchyma, and bathed as it were in its copious secretion ; moreover, coincidentally with the assumption of the parenchymal form, we found that a separate vessel conveying a different kind of blood was appropriated to the nutrition of the hepatic duct and its branches, and it seems certain that a different material is formed in the interior of the excretory ducts, from that which is produced so abundantly around them. May it not therefore be considered as far from improbable, that the absorption of the secreted material is effected by an action of endosmotic character, not however one of mere physical kind, but vital, *i. e.* peculiar in its nature, and producing, I believe, at the same time a change more or less considerable in the fluid absorbed*? One further proof may be adduced in the class

* It may be observed, that, supposing the nucleus to be the essential agent in the elaboration of all secretions, the structural condition of the ultimate hepatic ducts is just that, which is best fitted for the office I believe them to fulfill, of eliminating from the product of the surrounding cells the bile itself: moreover this condition, which might in some measure be regarded as the natural result of their diminution in size, corresponds precisely with what seems to be required by the function ascribed to them,—an accordance such as is rarely seen except in the actual works of nature herself.

of Mammalia of the relation obtaining between the condition of the liver and the amount of respiration: the cells of a porpoise's liver were granular nucleated bodies, containing rarely a single oil-drop; nor was there more than a very minute quantity of oil in a free state throughout the gland,—a contrast most complete to the condition of the hepatic parenchyma in its co-inhabitants of the watery element, which respire not by lungs, but by branchiæ.

Development.

The development of the liver is described by MULLER, with whom VALENTIN and others agree, as being formed on the fourth day of the incubation of the chick by a conical protrusion of the intestine, which soon acquires walls of considerable thickness, in the substance of which the ducts proceed to ramify; some of the "biliferous canals" however being apparently formed independently in the blastema itself. A different account is given by REICHERT, who states that the rudimentary mass of the liver, as well as that of the pancreas, is merely a cellular growth from the surface of what he calls "membrana intermedia," which appears to be a layer of cells developed from the germinal disc, corresponding to the vascular and mucous layers, and destined to give origin to the vertebral, cutaneous, and sanguineous systems, and the digestive system, with the exception of its mucous membrane.

The following observations fully confirm the opinion of REICHERT, so far as regards the independent origin of the liver; with respect however to some other points, the description which I venture to offer is in some degree different from any with which I am acquainted. On the morning of the fourth day I have found in the chick the chorda dorsalis and the rudiments of the vertebræ perfectly distinct; below these was a longitudinal fold with its convexity downwards, which was probably one of the "visceral laminæ;" towards the anterior part of this, and just behind the heart, there was a slight convex prominence, with a vascular free border, which appeared as a growth from the germinal membrane; this was probably the rudiment of the liver: no trace could be discerned of anything like an intestine. In another specimen about the same period, it was noticed that the developing vessels were very patchy and irregular, that in some parts there were merely spots or short streaks, and that though containing well-formed blood-globules, they did not appear to have distinct parietes. On the fifth morning the liver was quite distinct; it appeared as a somewhat reddish yellow mass situated just behind the heart, and presenting a free convex border below; above it ran the œsophagus curving forward and upwards, behind it was the stomach and the recently developed intestine. The border of the liver was pretty distinct in the whole of its circumference; a narrow space clearly intervened between it and the œsophagus and stomach, and there did not appear to be the slightest trace of the liver being derived from either of them; it seemed manifestly a separate and independent formation. The intestine distinguished from the œsophagus and stomach appears to be developed in the following manner, which I think has not

yet been correctly described. On the fifth day the constriction of the germinal membrane producing the vitelline duct was perfectly manifest, and the duct itself was filled with a dark oily mass contained in a distinct homogeneous membrane; this membrane constituting a complete sheath separated the cavity of the vitelline duct from that of the abdomen. It divided into two canals which took their course in nearly opposite directions; one ran forward and turned sharply upwards just behind the liver, and soon expanded into a somewhat dilated cavity. From this cavity several offsets were distinctly traced; one inclined upwards and a little forwards, widening as it proceeded, and soon opened into a transparent space with delicate but distinct parietes, which was evidently the stomach, as it opened at the other extremity into the œsophagus. A second offset, which was very distinct, passed upwards and backwards, and appeared to terminate in a cul de sac, but its destination could not be satisfactorily determined. From the anterior part of the intestinal cavity two less distinct offsets could be clearly traced proceeding into the liver; the upper one appeared to divide, but they could not be seen to ramify in the substance of the gland. The other canal proceeding from the vitelline duct ran backwards and upwards, and seemed clearly to be developing itself into the posterior part of the intestine, but was in a less advanced condition than that already described; at a subsequent period the two cæca, which afterwards attain so considerable a length, were seen sprouting out on either side from this portion of the intestine. Both these canals derived from the vitelline duct were filled with opaque oily contents, so that their course was most satisfactorily traced; they also presented a distinct homogeneous enveloping membrane, and some trace of an external layer of granular aspect which afterwards becomes much more marked, and which seems to be derived from the germinal membrane itself.

Towards the close of the sixth day a change had taken place in the condition of the stomach; it no longer distinctly communicated with the developing intestine, but appeared as a thick well-defined mass, into which the canal of the œsophagus ran, and terminated by a marked cæcal dilatation. The anterior prolongation of the vitelline duct formed a considerable curve with the convexity upwards, then descending became indistinct, and terminated near the lower convex border of the liver. Shortly before its termination, it gave off towards the liver a bulging process, which exhibited some traces of dividing, but did not nearly reach the margin of the gland; a circumstance which greatly surprised me, as I had fully expected that these offsets from the intestine to the liver would have proceeded to develop themselves into the hepatic duct, and not have retrograded as they thus appeared to do. Towards the end of the seventh day the stomach is completed and overlapped by the two lobes of the liver; the duodenal loop is also distinctly formed; in its concavity there is seen a curved elongated tract, which stretches up to the hilus of the liver and is there somewhat enlarged; it consists of cells, granular matter and nuclei, with an oily blastema, and is clearly the rudiment of the pancreas; as yet it has no connection with the intes-

tinal cavity. The liver consists almost wholly of nuclei and diffused oily and granular matter, without perfect cells; the hepatic vein is very large and distinct, and arises from a regular network of capillaries in the substance of the organ; no trace of hepatic duct has yet made its appearance; the primitive offset from the intestine is still further removed from the parenchymatous mass. The prolongations of the vitelline duct (anterior and posterior) have now thick walls, and their cavities are beginning to be formed; they are almost shut off from the vitelline sac, the duct appearing only as a yellow streak.

Near the end of the eighth day there was no remarkable change in the pancreatic mass contained in the duodenal loop; it manifestly had no connection by ducts with the intestine, but was truly a parenchyma. Close to the liver on the right of the pancreas there were seen two tubes; the left one of these could be traced down for a considerable way, but was lost shortly before it arrived at the lower part of the pancreas; it consisted of a distinct but very fine homogeneous tunic enclosing delicate cells which formed a kind of epithelium. The other tube was distinct only near the liver, where it expanded into a pyriform sac (the gall-bladder), the cavity of which was distinct, lined by cells and invested by an homogeneous tunic; from this dilatation the rudiment of the cystic duct extended only a very little way towards the intestinal cavity. Near the termination of the ascending portion of the duodenal loop, at the part where the remains of the original offset were still perceptible, the wall of the intestine was deficient, and there existed a semitransparent space leading to the opake contents in the interior; but this was soon lost, and did not extend upwards to the ducts near the liver. At the beginning of the ninth day the gall-bladder was completely formed, and presented a very distinct cavity; its duct ran down and communicated with the intestine; in the upper part of its course it was extremely distinct, being provided with an homogeneous tunic, and containing an abundant epithelium; towards its lower part its structure is less distinct, but its course was clearly indicated by a transparent space, continuous with its canal, and extending through the intestinal wall. The hepatic duct lay by its side; it also was more developed above than below, and indeed could not be followed quite into the intestine though its future course was quite clear; at its upper part it ran up to the liver, and seemed just to penetrate it, but how it terminated in this direction could not be determined; its diameter was nearly uniform throughout, about $\frac{1}{3\frac{1}{5}}$ th of an inch. Both cystic and hepatic ducts were clearly seen to join the intestine *just at the part where the primitive offset from the anterior prolongation of the vitelline duct existed*; this was still represented by an accumulation of opake oily matter at the spot, but there was no bulging of the intestinal wall. The liver consisted of nuclei, granular and oily matter, and perfect cells; throughout its parenchyma there were many bright yellow particles of bile.

By the first hour of the tenth day, the ducts of the gall-bladder and liver were perfectly formed, and communicated with the intestine at the exact spot where an

opaque mass still indicated the situation of the original offset from the intestine; the gall-bladder was quite visible to the naked eye, full of green bile, which was made, I think, by pressure to flow into the intestine. The pancreatic mass had now separated into two portions, skirting the contiguous margins of the duodenal loop; a rudiment also of its duct had begun to be developed; it appeared as a solid cylindrical tract of nuclei, continuous with a canal which entered the intestine together with the ducts from the liver. By the end of this day two pancreatic ducts were distinctly developed, one joining the hepatic just before its termination, the other entering the intestine together with the hepatic and cystic. I endeavoured to trace the further development of the hepatic duct with its branches in the substance of the liver, but without much success; it appeared to me however that they were first formed as solid tracts of nuclei, bearing some resemblance to the terminal ducts in the mature condition. The parenchyma of the liver now contained numerous particles of bright yellow or green bile; bile also filled the gall-bladder, and had flowed into the intestine.

The observations now related, warrant I think, the following conclusions:—

I. That the liver exists at one time as a parenchymatous mass, independent of any offset from the alimentary canal.

II. That though the first indications of the hepatic duct proceed from the intestine, yet these disappear, and are replaced by a separate and independent formation, which gradually develops itself further, both downwards to join the intestinal canal, and in the substance of the liver itself.

III. Biliary matter is formed in the hepatic parenchyma before its communication with the duodenum is freely established.

The following propositions may serve as a *resumé* of the principal conclusions to which we have been led during our survey of the various forms of hepatic structure.

The liver in all vertebrate animals may be regarded as consisting of a secreting parenchyma and excretory ducts.

The size of the excretory apparatus bears only a small proportion to that of the secretory.

These two portions of the liver are not continuous with each other, but disposed simply in a relation of juxtaposition.

The action of the liver seems to consist in the transmission of the bile as it is formed from cell to cell, till it arrives in the neighbourhood of the excretory ducts by which it is absorbed. This action is probably slow, and very liable to be interfered with, contrasting remarkably with that of the kidney, where a particular apparatus is added to ensure completeness and rapidity of action.

The secretion of the hepatic cells is very liable to be retained within the gland, either in the cells or in a free state.

This circumstance, as well as its structural peculiarities, seem to point out the liver as approximating to the class of ductless glands.

For the same reason it seems highly probable, that a part of the secretion of the cells is directly absorbed into the blood which traverses the lobules.

In a classification of the true glands the liver seems to occupy the lowest position, the highest being assigned to the permanently tubular, such as the kidney and testis.

From the condition of the secreting parenchyma in many instances, we learn that the secretory process by no means requires the formation of perfect cells in order to effect its peculiar changes; these may certainly occur in blastematous matter if a nucleus only be present.

The condition of the liver is in great measure dependent on the intensity of the respiratory process; its products being unused accumulate in the gland, often to a remarkable extent; its function is therefore not only vicarious of respiration, as formerly supposed, but preparatory, and to some extent subsidiary.

In concluding these inquiries, I cannot but acknowledge the kind assistance I have received from my friend Mr. P. HEWETT, and also from Mr. H. GRAY, who has several times aided me with his acute observation when a doubtful point was to be decided.

APPENDIX.

An objection may be urged against the account which I have given of the relation of the ultimate ducts to the cells of the liver, to the effect that they are in contact with these particles to so small an extent, that it is difficult to understand how the bile which they secrete should be received into the efferent ducts.

In answer to this I observe, first, that I believe much of the secretion of the cells is directly absorbed into the blood traversing the lobules.

Second, that I think it is by no means proved that the secretion of the cells is perfectly formed bile; in many instances it clearly is not: thus, in most fishes and in the fatty liver of the human subject, it is evident that the gorged parenchyma is full, not of bilious, but of oily matter, *out* of which however healthy bile is elaborated. I have carefully examined the cells of the human liver, in organs which were quite healthy, without finding any evidence of the presence of bile in their contents, though in congested livers the yellow molecules are often very distinct in the interior of the cells. In the Pig, Rabbit and Dog, the cells appear as pale granular bodies, and do not, that I can perceive, exhibit the least biliary tinge, even after the addition of nitric acid. In the Sheep there is generally a good deal of oily matter in the cells, but no biliary. I do not of course deny that bile is often formed in the cells, especially in states of congestion, but I conceive that in the perfectly healthy state, the complete elaboration of bile is effected principally by the nuclei of the terminal portions of the ducts.

EXPLANATION OF THE PLATES.

PLATE IX.

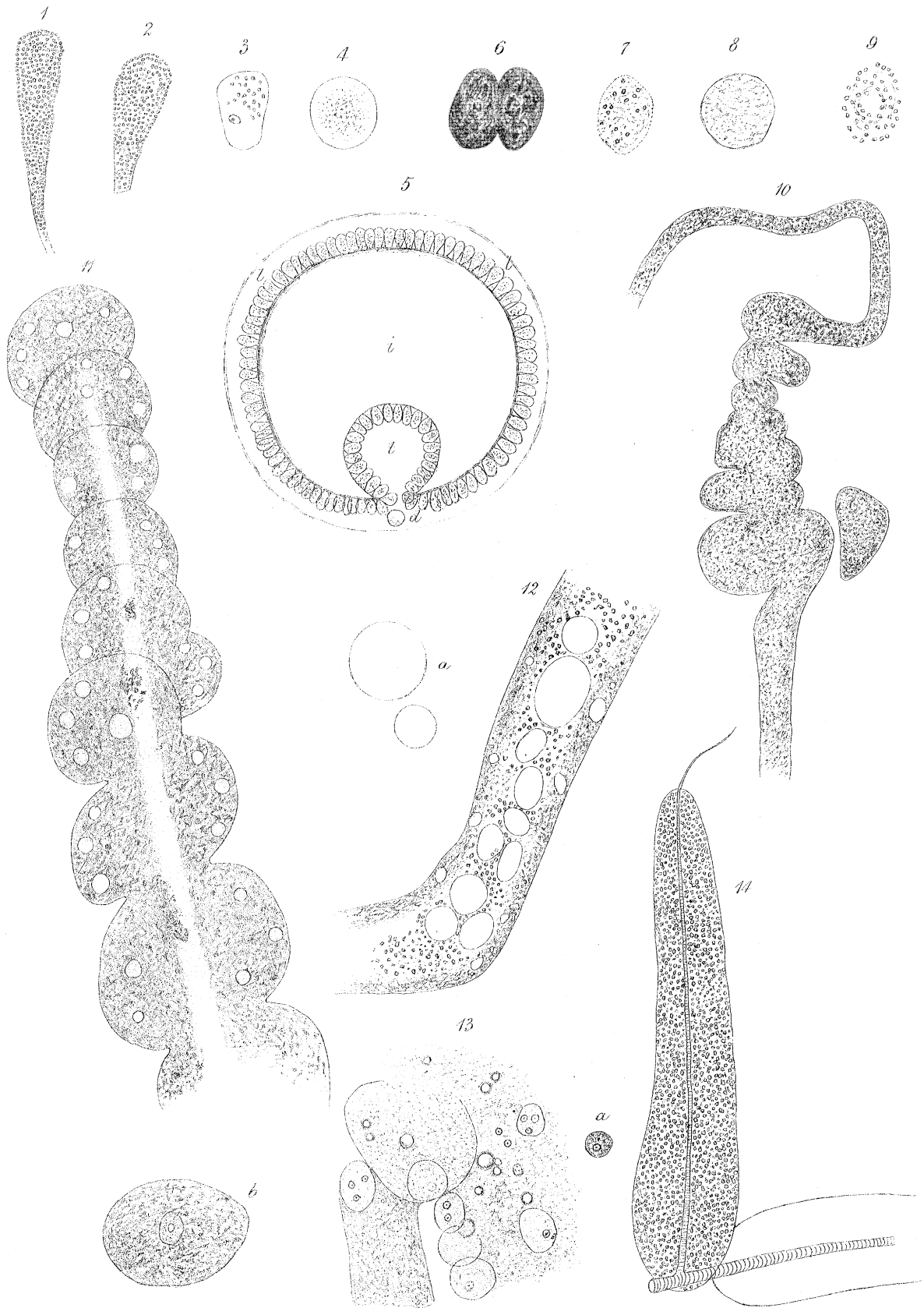
Figs. 1, 2, 3, 4 represent cells from the liver of the Earthworm; (1) and (2) are elongated and filled with spherules of biliary matter; the envelope is prolonged into a tubular neck in (1.), diameter about $\frac{1}{1500}$ th of an inch. (3.) has a delicate envelope, a nucleus, and some biliary contents, diameter $\frac{1}{666}$ th of an inch. (4.) has a distinct envelope enclosing only pale granular matter, diameter $\frac{1}{857}$ th of an inch.

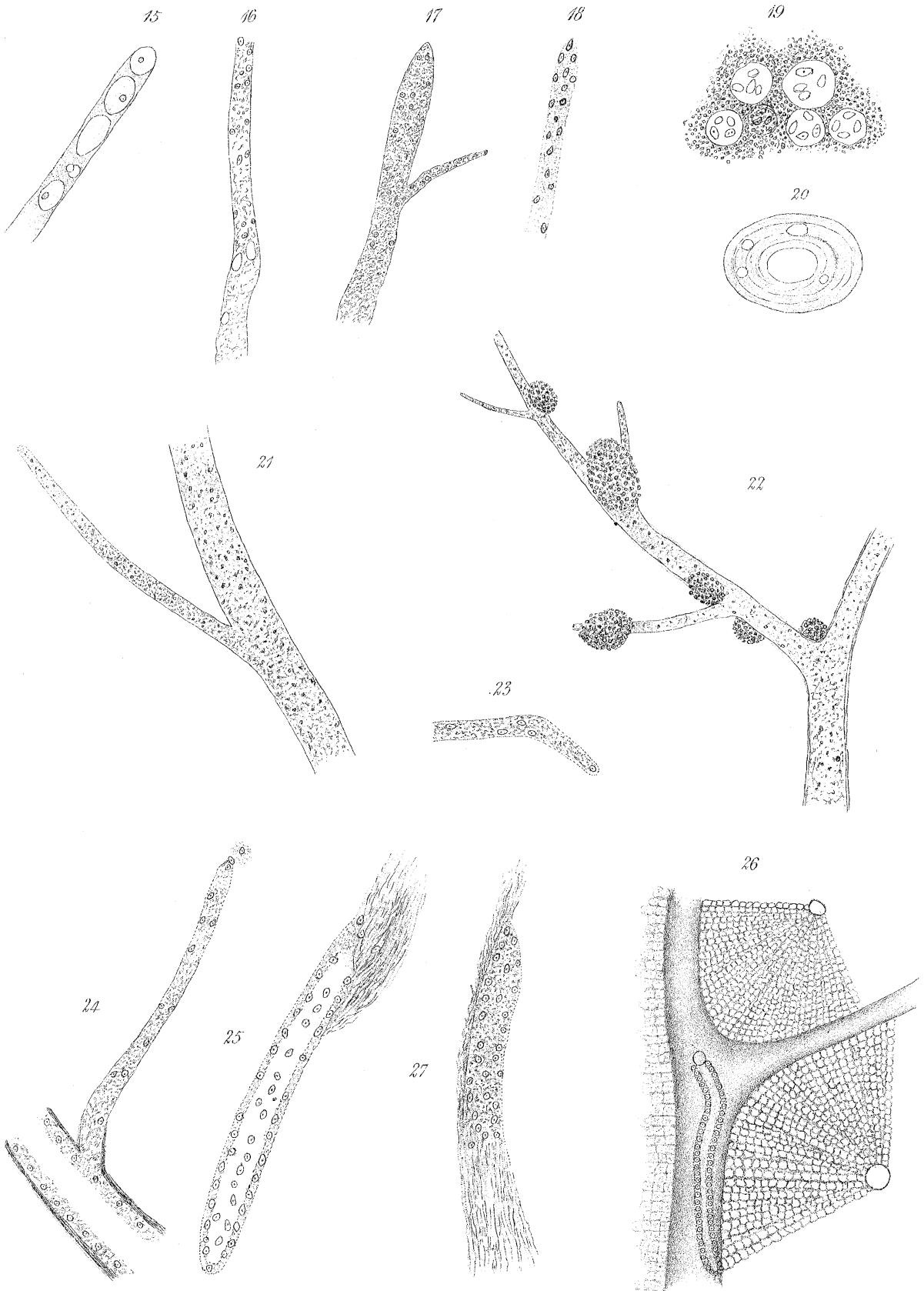
Fig. 5 is an ideal section of an Earthworm, showing the relation of the typhlosole to the cavity of the intestine. The hepatic stratum on the exterior of the intestine is seen to be continuous with that in the typhlosole; *i* is the intestinal cavity; *t*, that of the typhlosole; *d*, the dorsal vessel in contact with *l*, *l*, *l*, the hepatic stratum.

Figs. 6, 7, 8, 9, 10 are taken from examination of the liver in the Leech. (6) represents two cells full of dark biliary contents cohering together. (7) a cell containing pale amorphous matter in which some biliary spherules have begun to appear, diameter $\frac{1}{857}$ th of an inch. (8) is a cell containing only pale granular matter, no perceptible nucleus, diameter $\frac{1}{666}$ th of an inch. (9) is a cell apparently dissolving; it has no envelope, and the biliary spherules are separating from each other, diameter $\frac{1}{1000}$ th of an inch: in the centre there is a clear cavity which was observed in many others, as if the minute spherules were repelled outwards by some force. (10) a tube with several irregular bulgings, indicating the coalescence of the component cells; one cell is seen lying close by the side of the tube, but not yet united to it: the envelope of this tube was very faint in most parts; it almost resembled a solid tract of biliary matter.

Fig. 11. An hepatic tubule from the Blowfly (*Musca vomitoria*); it seems to be made up of a series of vesicles which overlie each other: the outlines of all are extremely distinct, and they all communicate together, being traversed by a central canal. It is not certain whether the first vesicle be truly the origin of the tube, or whether it has been detached from others with which it was in connection; there can, however, be no doubt that the specimen represents a tube very near, if not quite at its origin. The basement tissue of the tube was very conspicuous; it enclosed a great quantity of yellowish granular matter, in which were imbedded some transparent cells. In some parts of the central canal there were patches of opaque oily matter; the diameter of the tube at its origin was $\frac{1}{200}$ th of an inch; near its lower part $\frac{1}{143}$ rd of an inch.

Fig. 12. Portion of hepatic tube from large white Moth; its diameter is $\frac{1}{300}$ th of an





inch. It consists of an investing basement membrane, which is strongly marked; this supports a layer of pale granular matter, in which are imbedded several small transparent cells: the cavity of the tube is wide, and is occupied by numerous very delicate transparent cells, in the interstices of which are dark clusters of biliary granules. At *a*, two of the transparent cells are shown which had escaped from the tube; they are perfectly globular and contain only a limpid fluid; they are, I think, of constant occurrence in the hepatic tubes of insects.

Fig. 13. View of parenchymatous portion of the Blowfly's liver (or adipose tissue) in early stage of its formation. Several nucleated cells, diameter $\frac{1}{750}$ th of an inch, containing granular matter, are seen lying in a pale granular blastema, along with several large oil-globules; a vesicle and tube are in process of formation from the blastema: these will include one or more nucleated cells. (*a*) is a nucleated cell from the blastema, diameter $\frac{1}{2400}$ th of an inch, probably an early condition of the larger cells; (*b*) a fully-formed vesicle, diameter $\frac{1}{222}$ nd of an inch, containing yellowish granular matter, and a nucleated cell.

Fig. 14. An elongated vesicle, $\frac{1}{24}$ th of an inch long, $\frac{1}{111}$ th of an inch wide at its middle, formed of an homogeneous membrane, enclosing dark oily contents; it is traversed in its whole length by a minute tracheary tube, which having become very fine issues from it at its upper extremity. (From brown Moth.)

PLATE X.

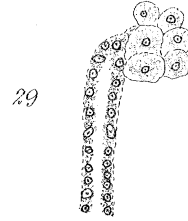
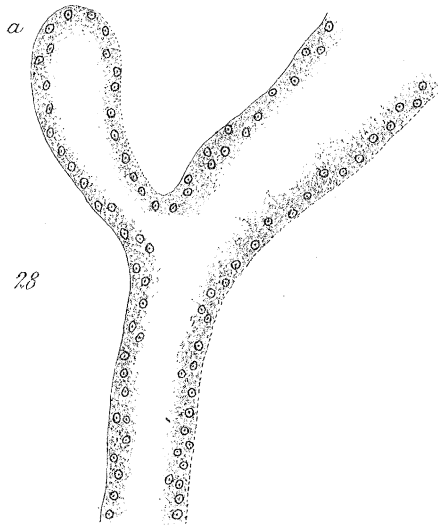
Figs. 15, 16, 17 from liver of Tench; they represent minute biliary ducts isolated from the parenchyma. (15) exhibits a delicate homogeneous tubular membrane, in the interior of which are several large delicate epithelial cells; the last of these lay so close to the extremity of the specimen, that it could not be determined whether the homogeneous membrane formed an actual caecal termination; diameter $\frac{1}{2000}$ th of an inch. (16) exhibits at its lower part the tubular character; towards its termination this is lost: it has the appearance of a tract of granular matter with even borders; several nuclei can be discerned in it; diameter $\frac{1}{2000}$ th of an inch. (17) is a duct, $\frac{1}{750}$ th of an inch diameter, consisting of nuclear granules and granular matter; its extremity is quite even, though it is difficult to determine whether it is completely invested by homogeneous membrane.

Fig. 18. A minute duct, probably terminal, from liver of Perch; its diameter is $\frac{1}{3000}$ th of an inch: it consists of distinct nuclei, set as it were in a faintly mottled basis-substance.

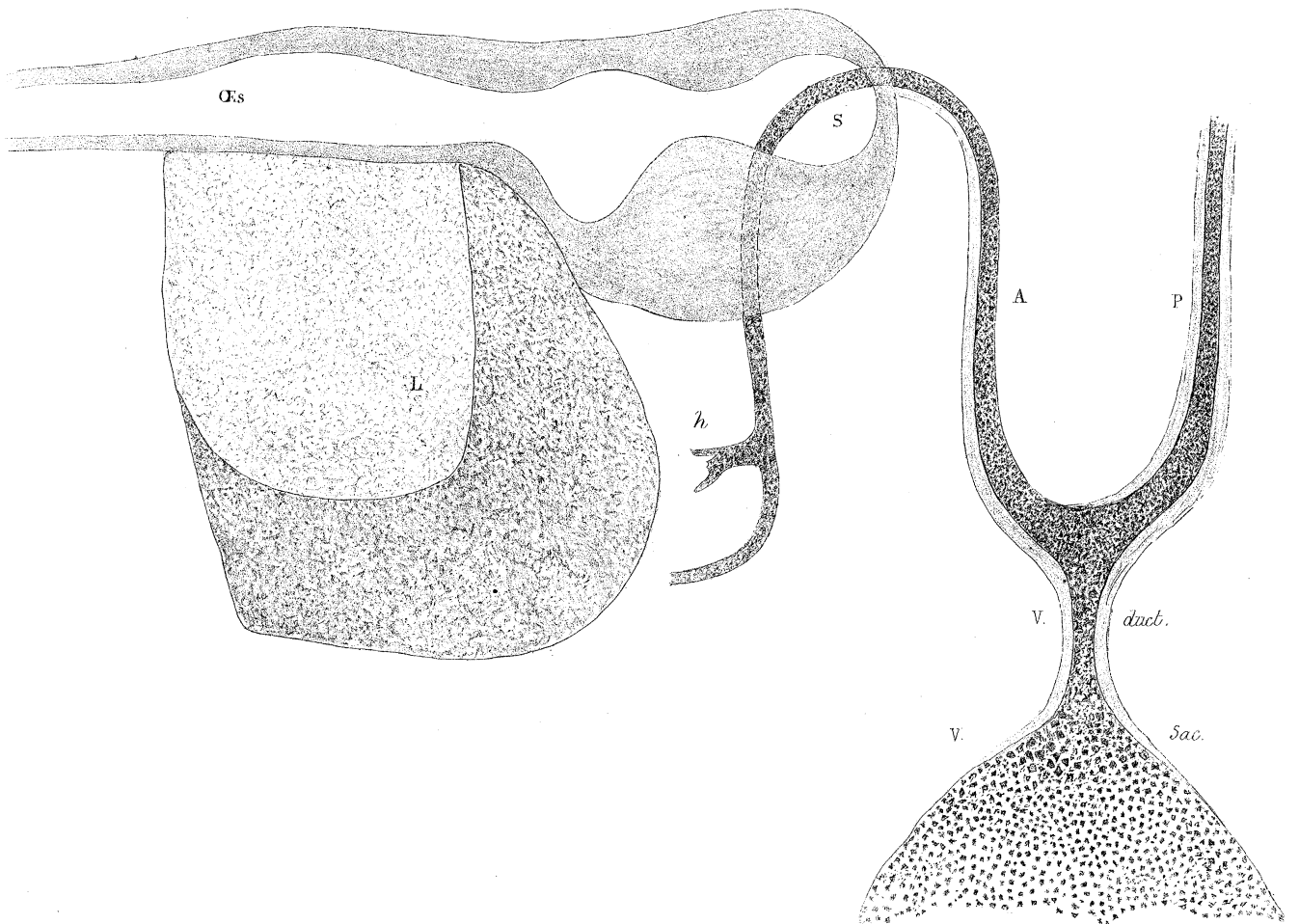
Fig. 19. A group of peculiar cells from the parenchyma of liver of Mackerel; their diameter varies from $\frac{1}{1500}$ to $\frac{1}{1000}$ th of an inch. They have a well-marked

envelope, and contain 3-5 circular or oval vesicles, which have somewhat the aspect of nuclei: the whole group of cells are imbedded in a collection of yellow granules of rather large size.

- Fig. 20. One of the vesicles occurring in the parenchyma of the Skate's liver. The central cavity is shown with traces of surrounding laminæ concentric to the envelope, between which are some small vesicles: long diameter about $\frac{1}{330}$ th of an inch; short $\frac{1}{400}$ th of an inch.
- Fig. 21. A rather large branch of the hepatic duct, diameter $\frac{1}{500}$ th of an inch; its walls consist of homogeneous membrane with investing fibrous tissue; its cavity is filled with nuclear granules, finely granular matter and oil-globules; from its side there springs off a minute branch, which tapers evenly to its termination; its diameter is $\frac{1}{1500}$ th of an inch; near its origin it has a distinct homogeneous tunic and a little fibrous investment; towards its extremity the homogeneous membrane can no longer be discerned, though the margins are even and the extremity rounded, and there is not the slightest appearance of its having suffered injury; it is I believe really a terminal branch becoming resolved, as many others are seen to be, into a delicate tract of granular matter; in some of these, as in fig. 16, nuclei are manifestly to be found; in others they are scarcely perceptible, or apparently absent. (From Flounder.)
- Fig. 22. A large branch of the hepatic duct with several minute offsets; some of these, as well as the main branch, have pretty large yellow masses of biliary matter adhering to their exterior. The interior is filled with nuclear granules and granular matter. (From Tench.)
- Fig. 23. A small, probably terminal, duct from liver of Grass Snake; it tapers from $\frac{1}{2000}$ th to $\frac{1}{3000}$ th of an inch; its extremity is rounded; no basement membrane can be discerned; it seems to consist of nuclei set in a finely mottled substance.
- Fig. 24. A branch of the hepatic duct, with a minute lateral offset from liver of Duck. The parent branch has an homogeneous tunic with fibrous investment; on its interior there is a granular epithelial layer, in which nuclei are but faintly discernible; the offset is $\frac{1}{125}$ th of an inch in length, and $\frac{1}{3000}$ th of an inch wide near its termination; it gives off no branches; in the greater part of its extent it has a tunic of basement membrane enclosing nuclei dispersed through granular matter; its terminal extremity was somewhat obscured, being in contact with some remains of parenchyma, but I am inclined to think it was closed; another specimen from the same was distinctly seen to terminate by a closed extremity.
- Fig. 25. A minute duct from liver of Sheep perfectly isolated from other structures; its diameter is $\frac{1}{1000}$ th of an inch, its length $\frac{1}{111}$ th of an inch; it gives off no branches; its extremity appears to be closed; it has perfectly defined



30



margins, but no basement membrane can be detected by the most careful scrutiny ; it consists of nuclei set in a partly granular, partly amorphous basis-substance ; it issues from a quantity of fibrous tissue, which is seen at the upper part.

Fig. 26. View of a terminal duct from liver of Sheep lying in an interlobular fissure ; it commences in a "space," and is seen clearly not to give off any branches in its whole extent, as it runs along the fissure ; its extremity, I am nearly sure, was closed, though it was rather obscured by the investing membrane, under which it dipped as it approached the side of the lobule ; the length of this duct was $\frac{1}{94}$ th of an inch ; its diameter, $\frac{1}{857}$ th of an inch, was nearly uniform throughout ; its walls were formed by nuclei of great distinctness, set close together in an amorphous basis-substance ; no basement membrane could be positively said to exist ; the hepatic duct had been injected, and a small mass of the colouring material was seen occupying the cavity of the minute duct where it lay in the interlobular "space."

Fig. 27. A minute duct, diameter $\frac{1}{1500}$ th of an inch, from Human liver ; it lies in a tract of fibrous tissue, from which however it is quite distinct ; on its right margin there seems to be a delicate homogeneous membrane, but it ceases before the extremity ; this is perfectly even, and evidently has not suffered injury ; the duct chiefly consists of nuclei set in a subgranular basis-substance.

PLATE XI.

Fig. 28. A biliary duct from liver of Bullock with a lateral terminal branch ; the walls chiefly consist of nuclei and granular matter, and are not invested by a distinct basement membrane except at *a* ; the margin however is quite even ; diameter of terminal extremity $\frac{1}{666}$ th of an inch.

Fig. 29. Terminal duct from Human liver, diameter $\frac{1}{1500}$ th of an inch ; it is not invested by basement membrane, but consists of nuclei set in a faintly granular basis-substance ; at its extremity it lies in contact with a group of hepatic cells.

Fig. 30. View of œsophagus, stomach, liver and intestine of Chick towards end of 6th day of incubation. *Œs.* œsophagus. *S.* stomach. *L.* liver ; its two lobes are represented. *V. sac,* Vitelline sac. *V. duct,* Vitelline duct. *A.* anterior prolongation of vitelline duct. *P.* posterior prolongation of vitelline duct. *H.* offset to liver, primitive rudiment of hepatic duct.